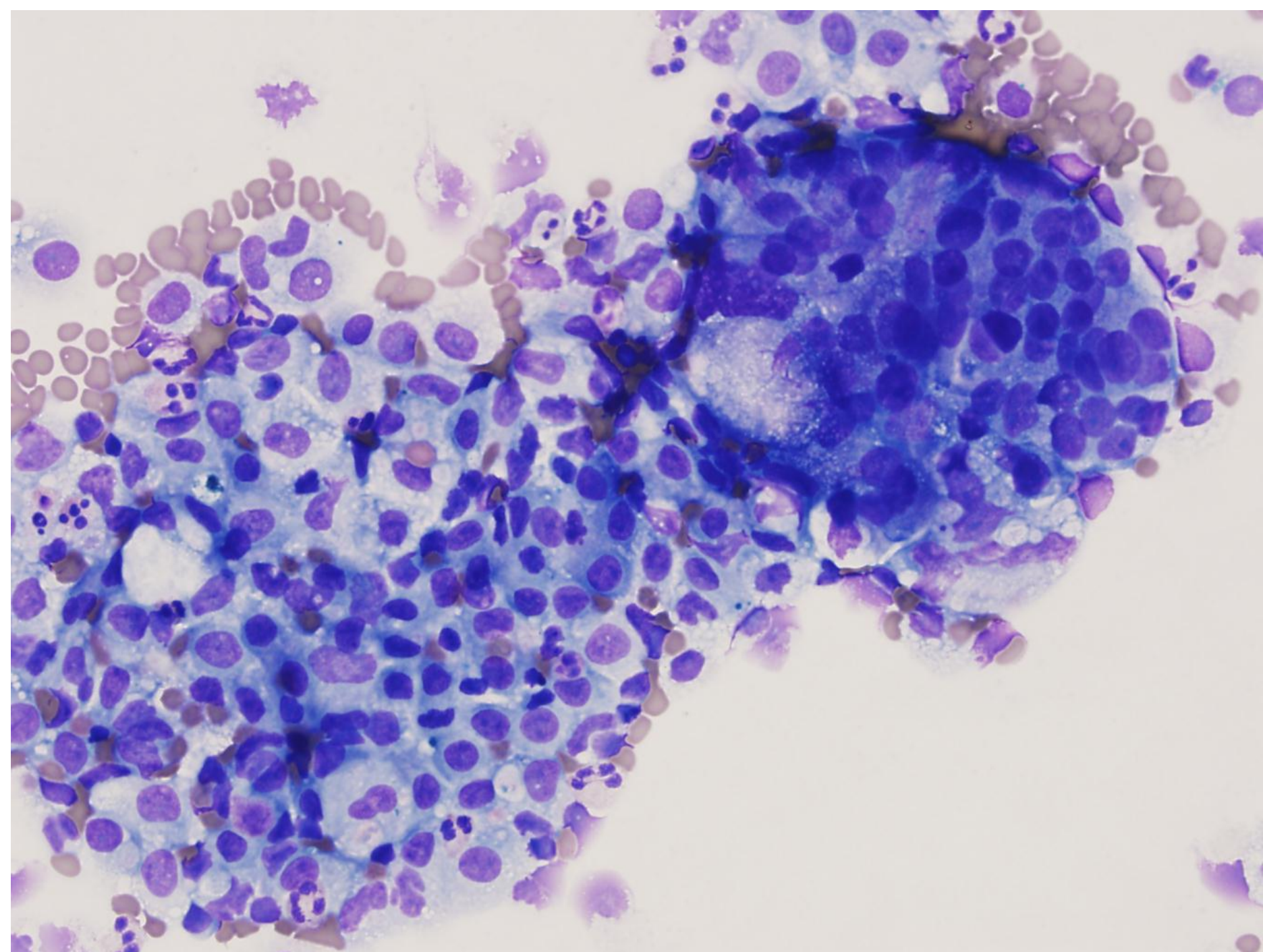
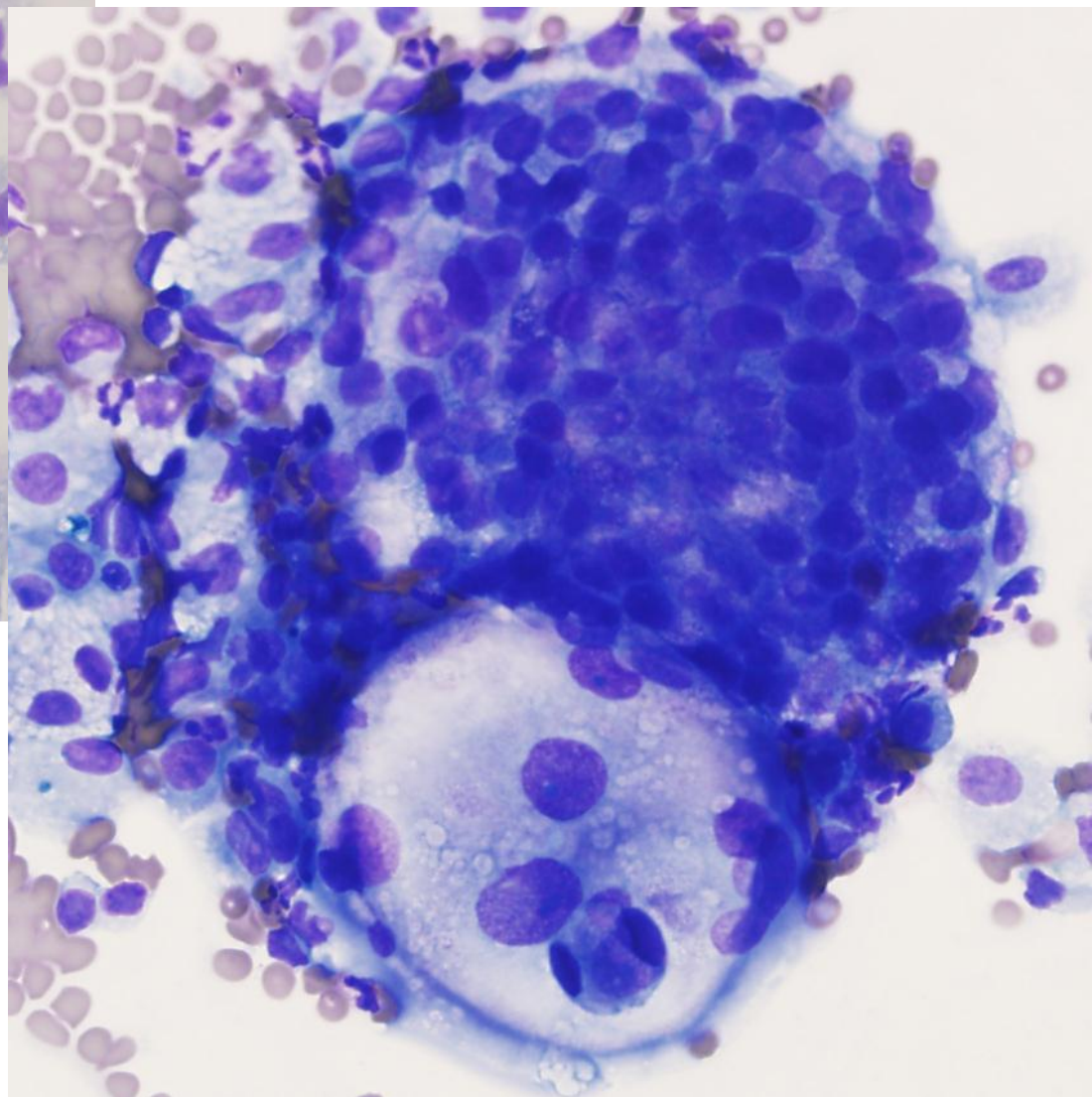
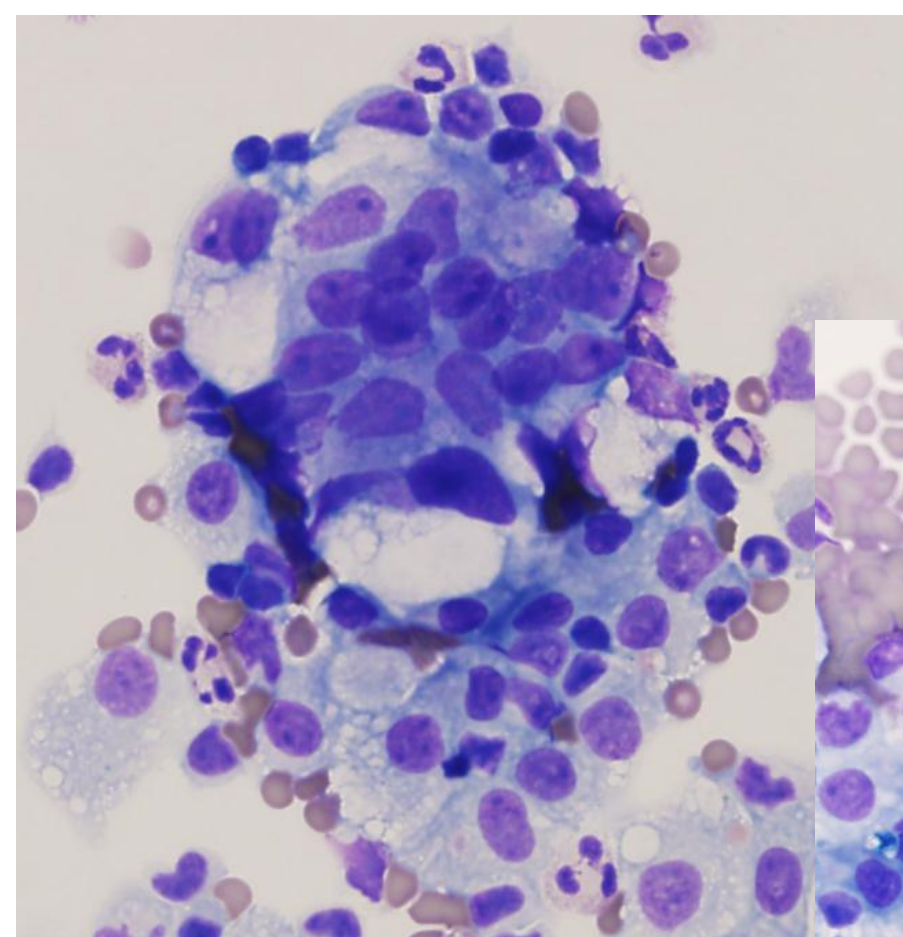


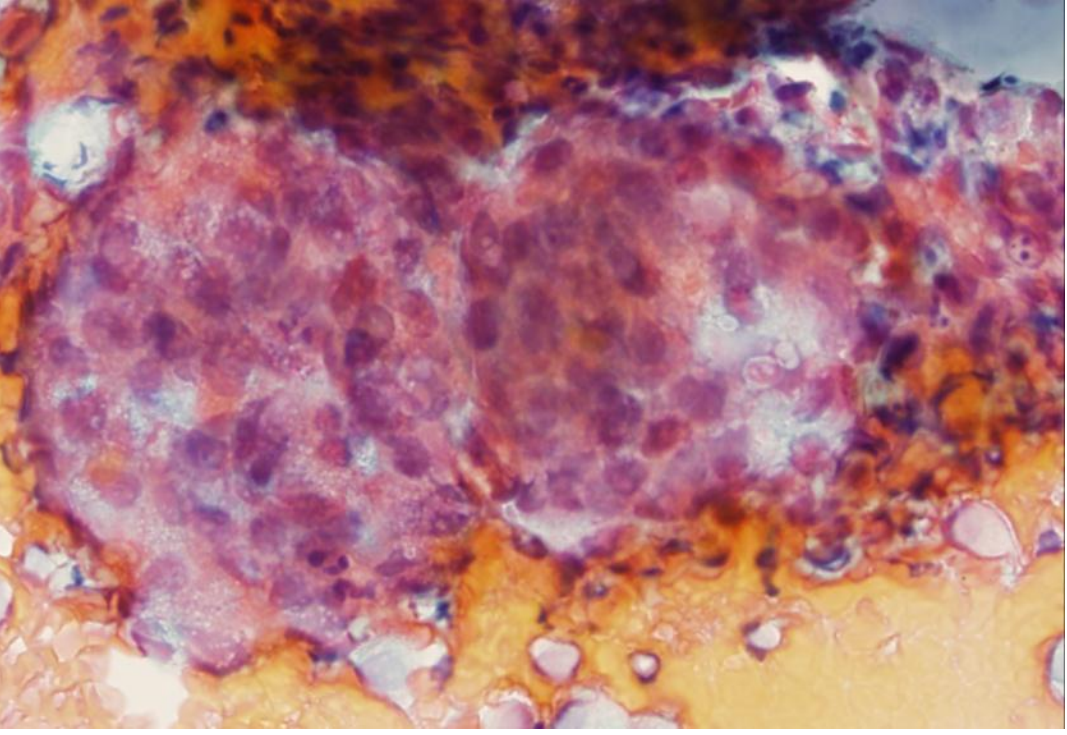
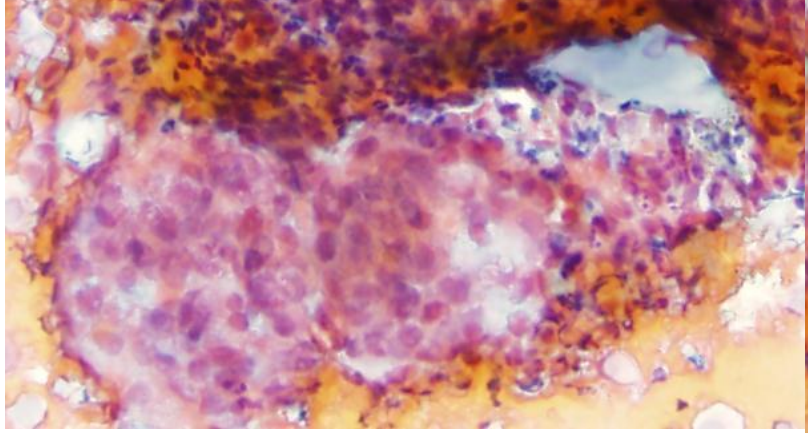
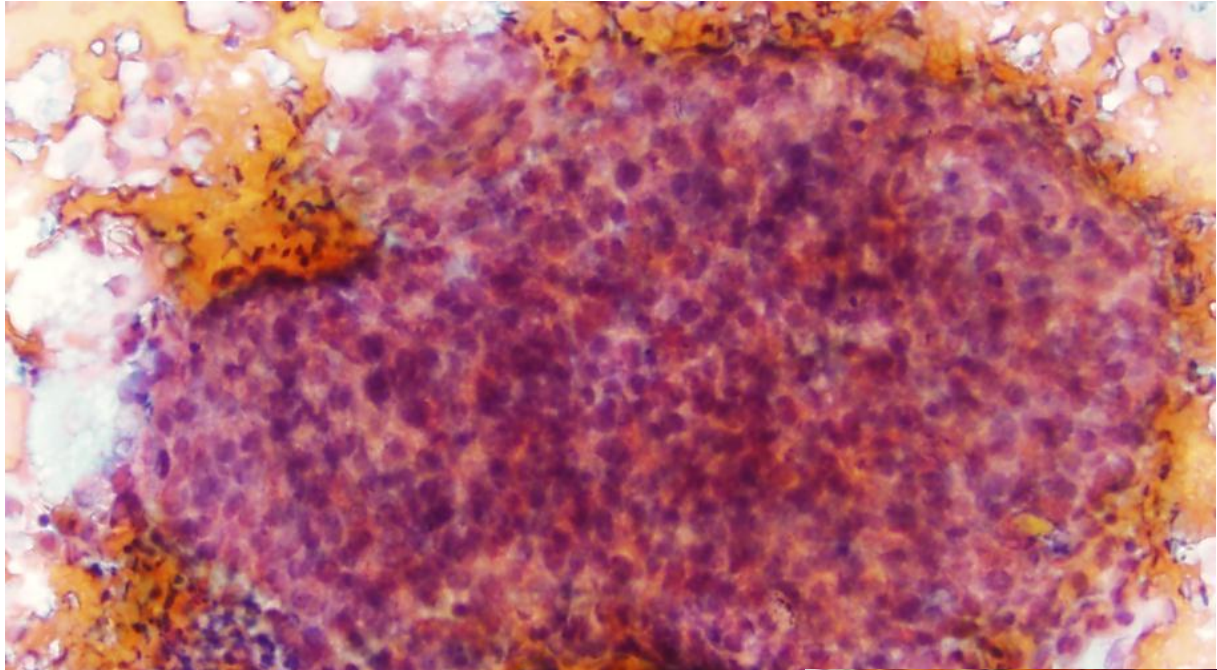
Interesting Case Conference

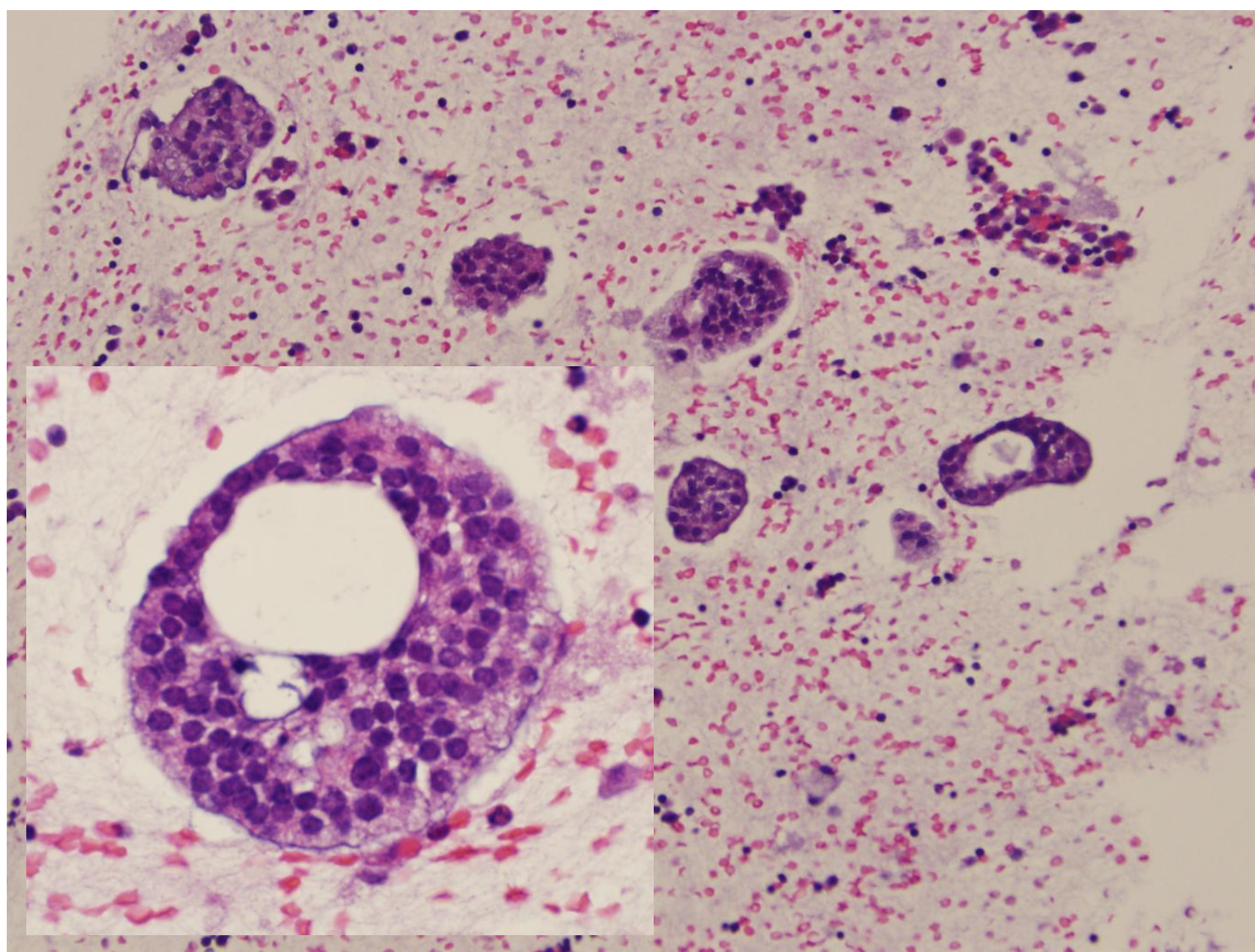
Hx

- 66 year old man
- Consult case
 - Peritoneal/pelvic fluid
- Pt has hx of prostate cancer
 - Details unknown



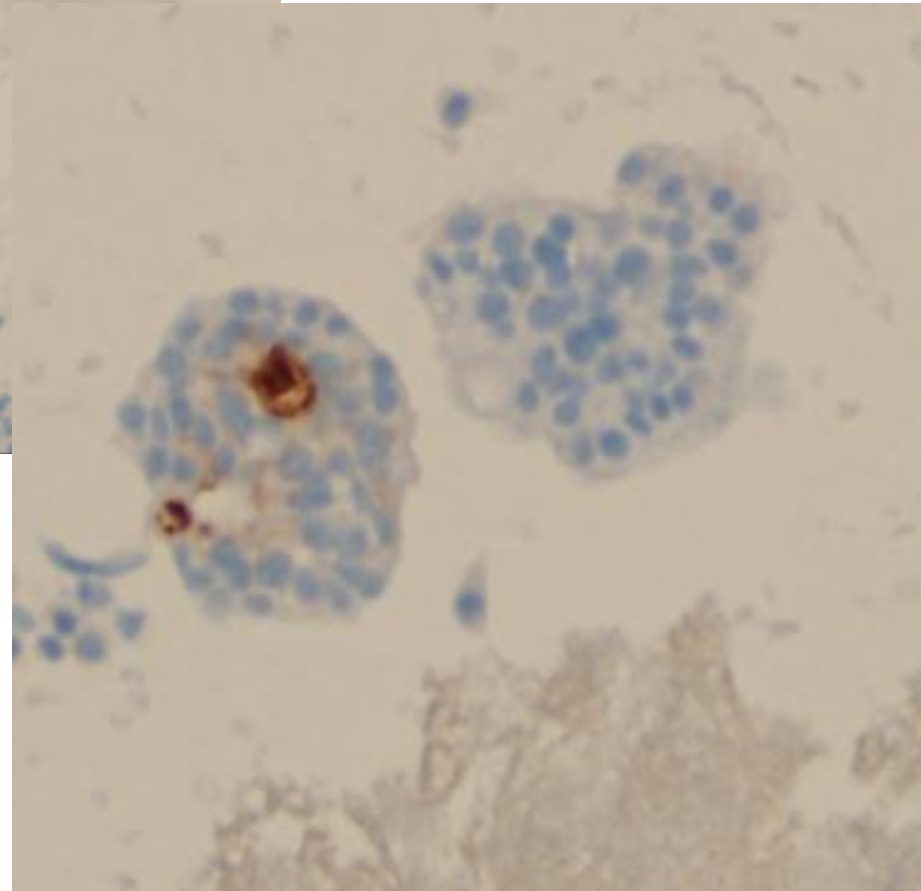
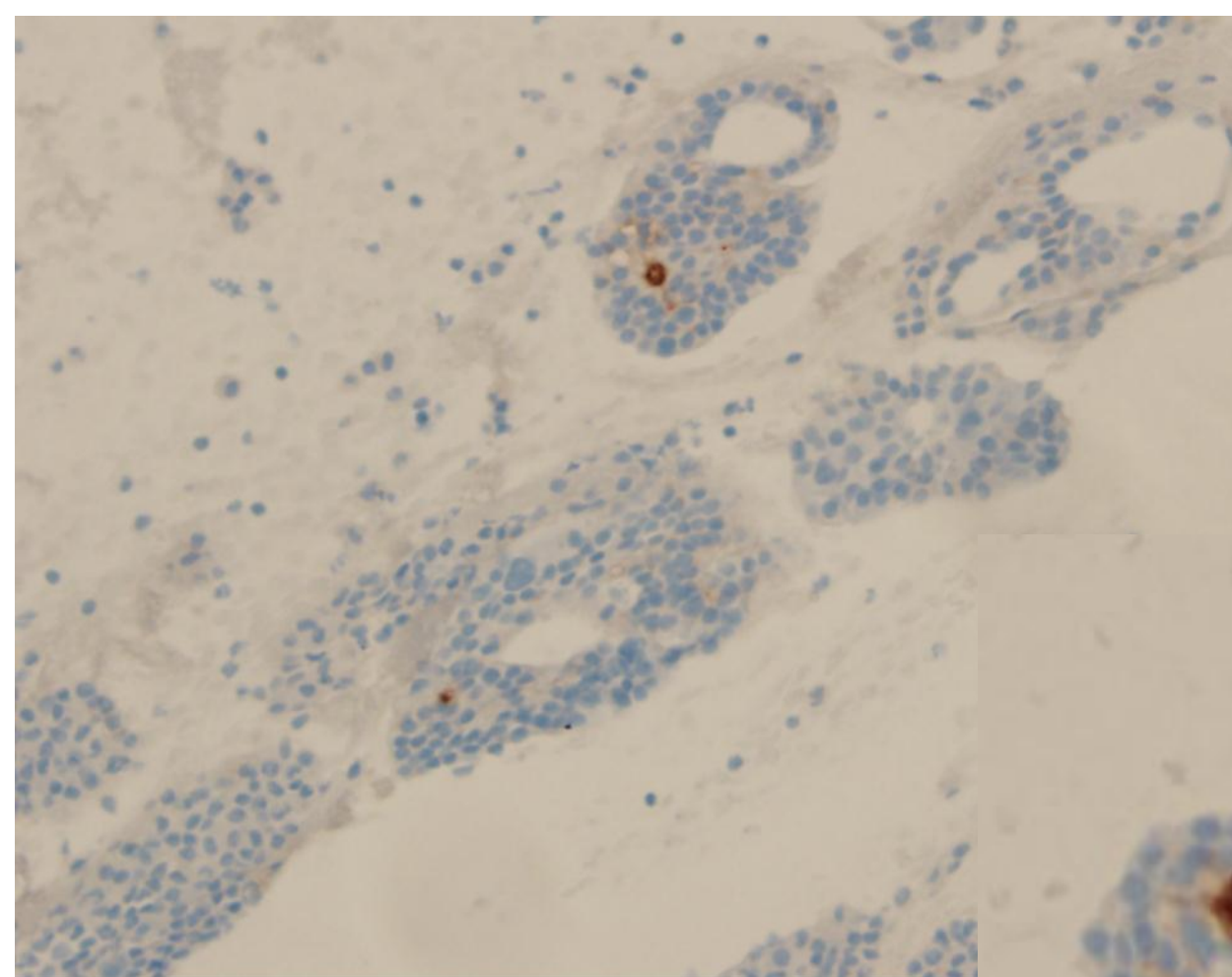






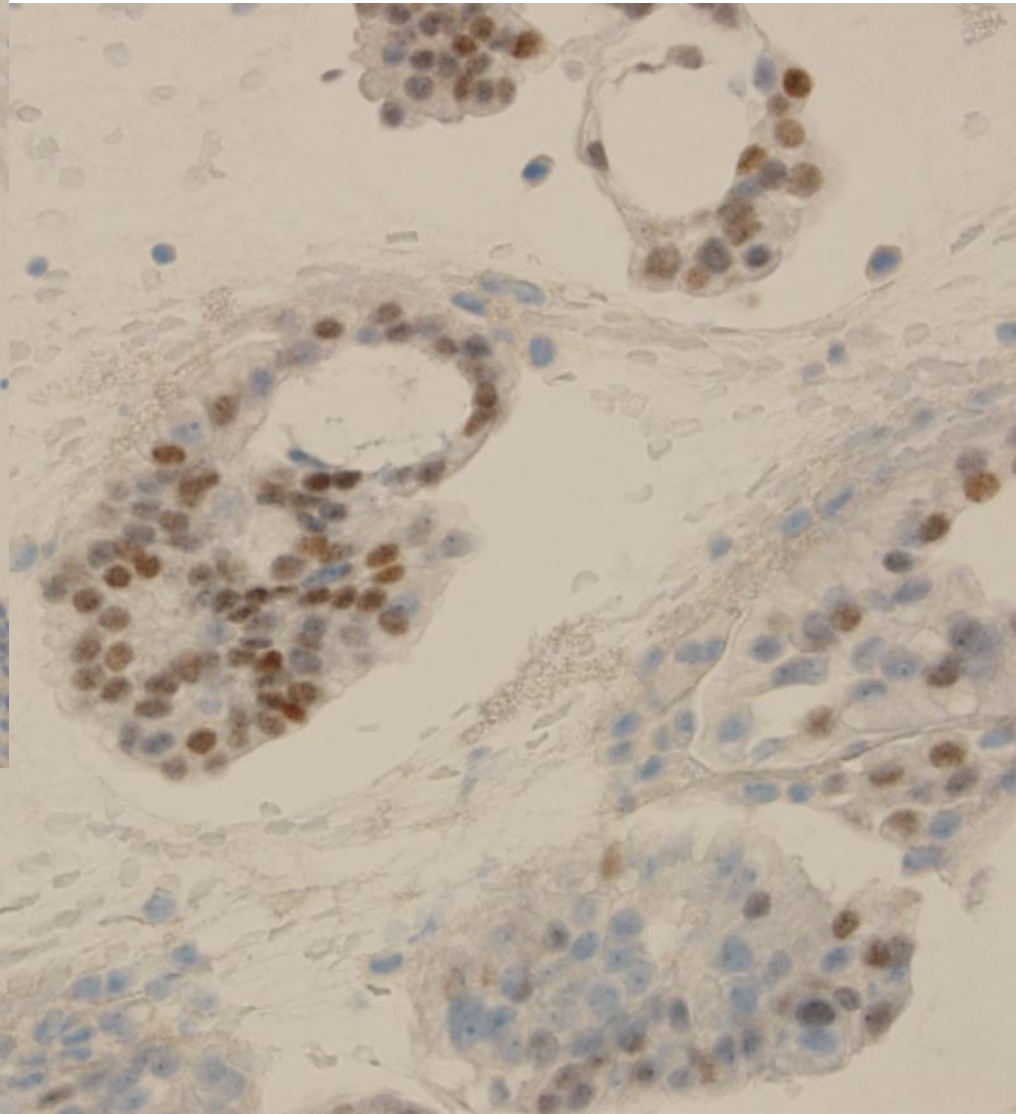
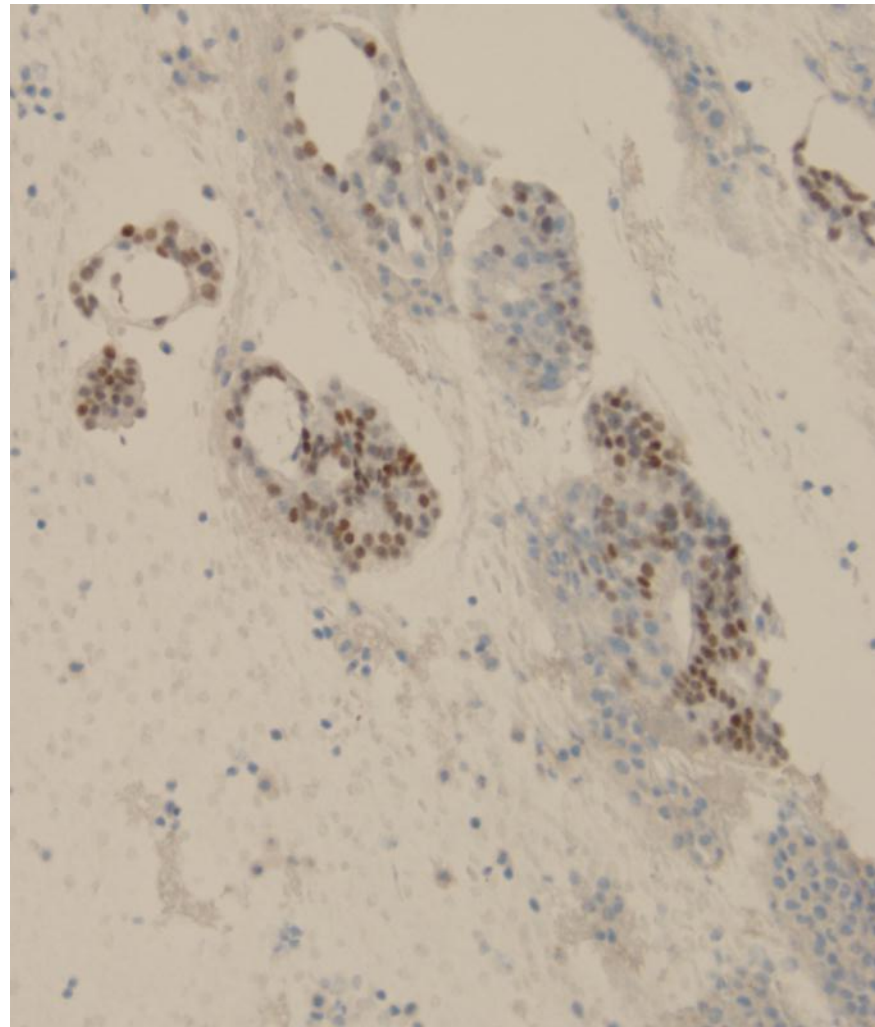
OSH IHC

PSA



OSH IHC

CDX-2



DDX

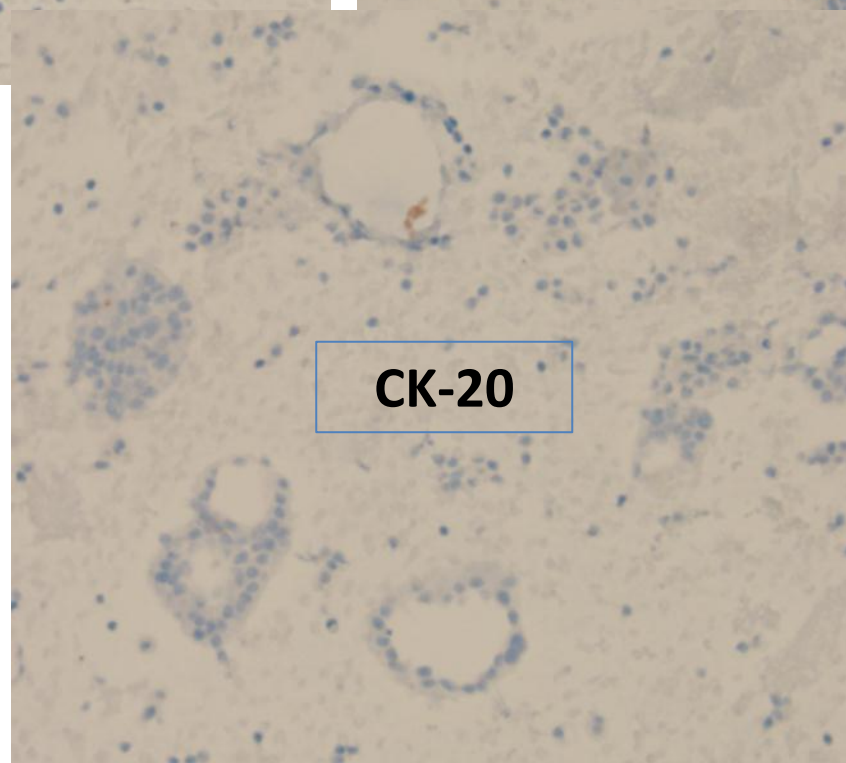
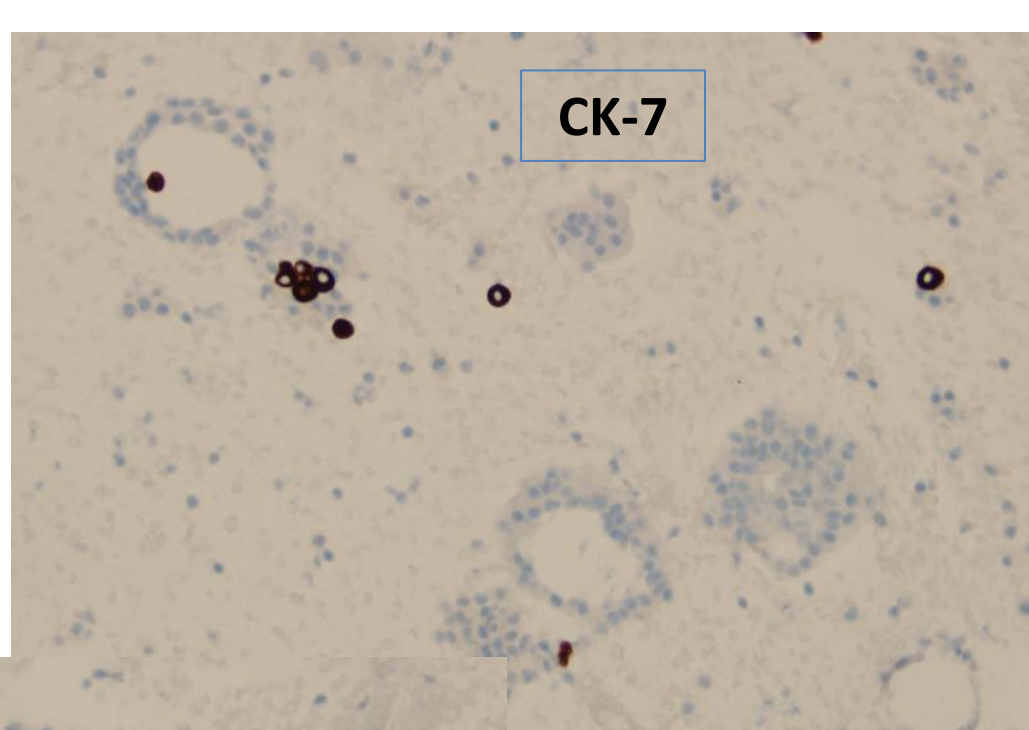
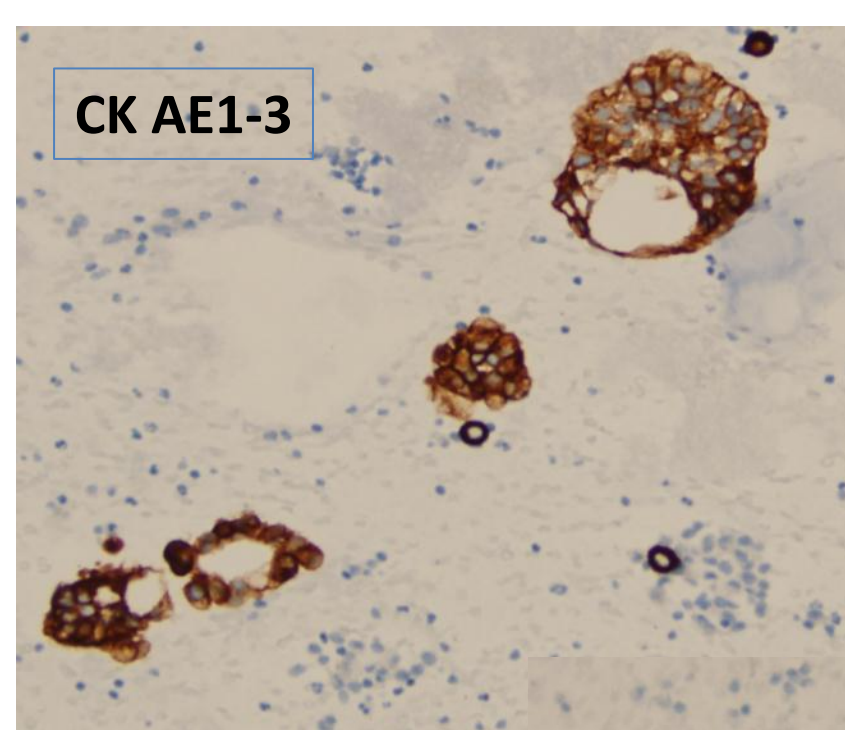
- Prostatic
- Colon
- UCC
- Other carcinoma / adenocarcinoma

Reason for consult: prostatic vs. colon

CK AE1-3

CK-7

CK-20





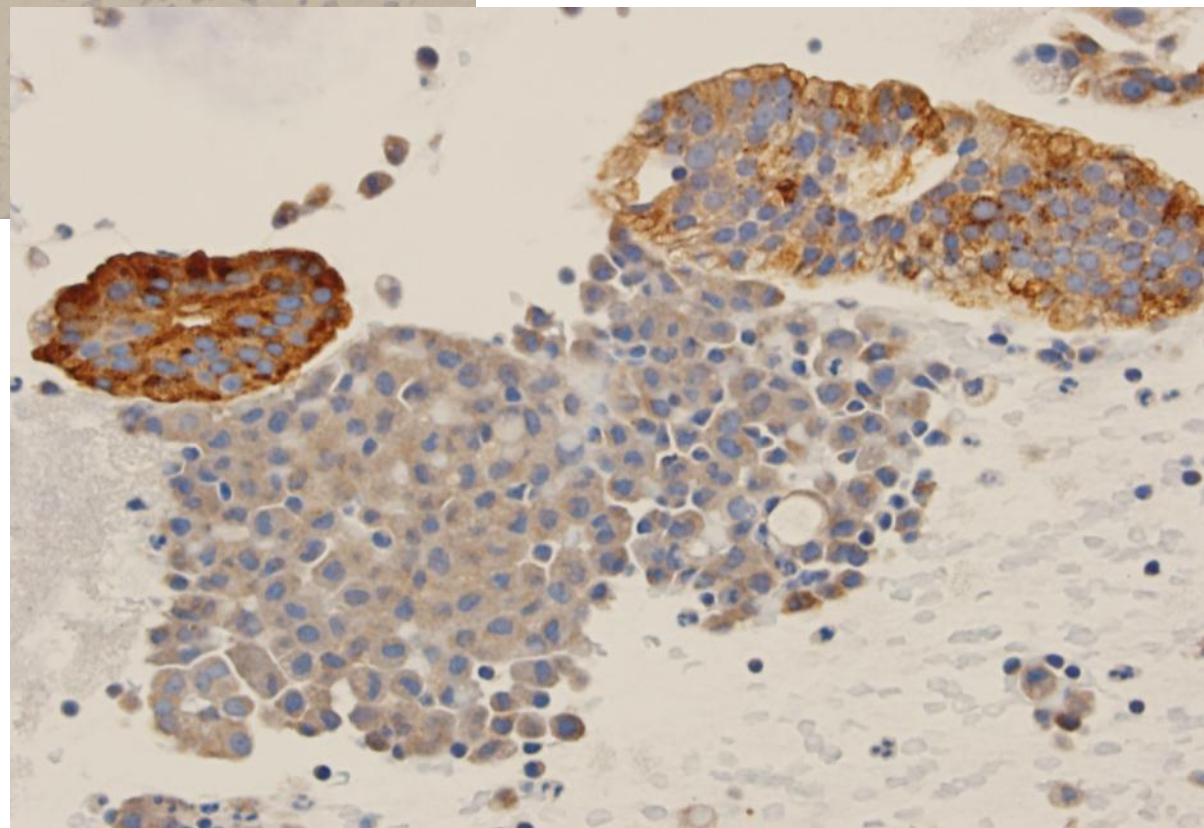
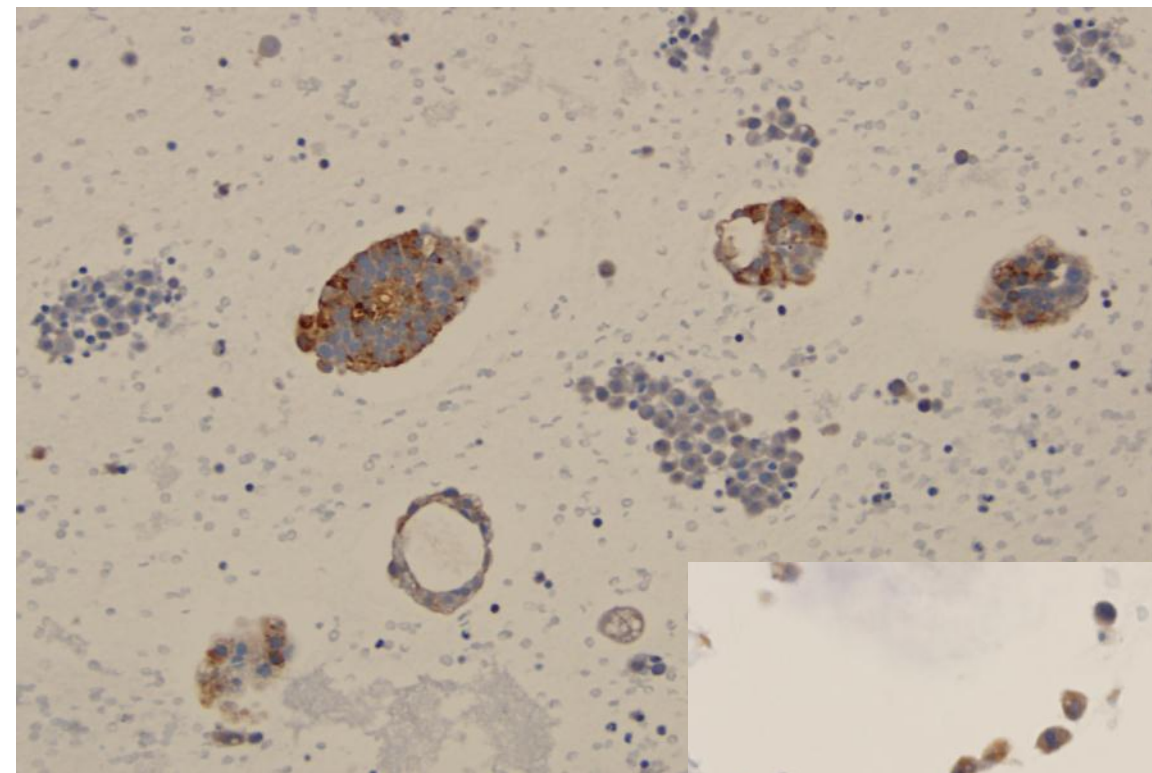
CEA



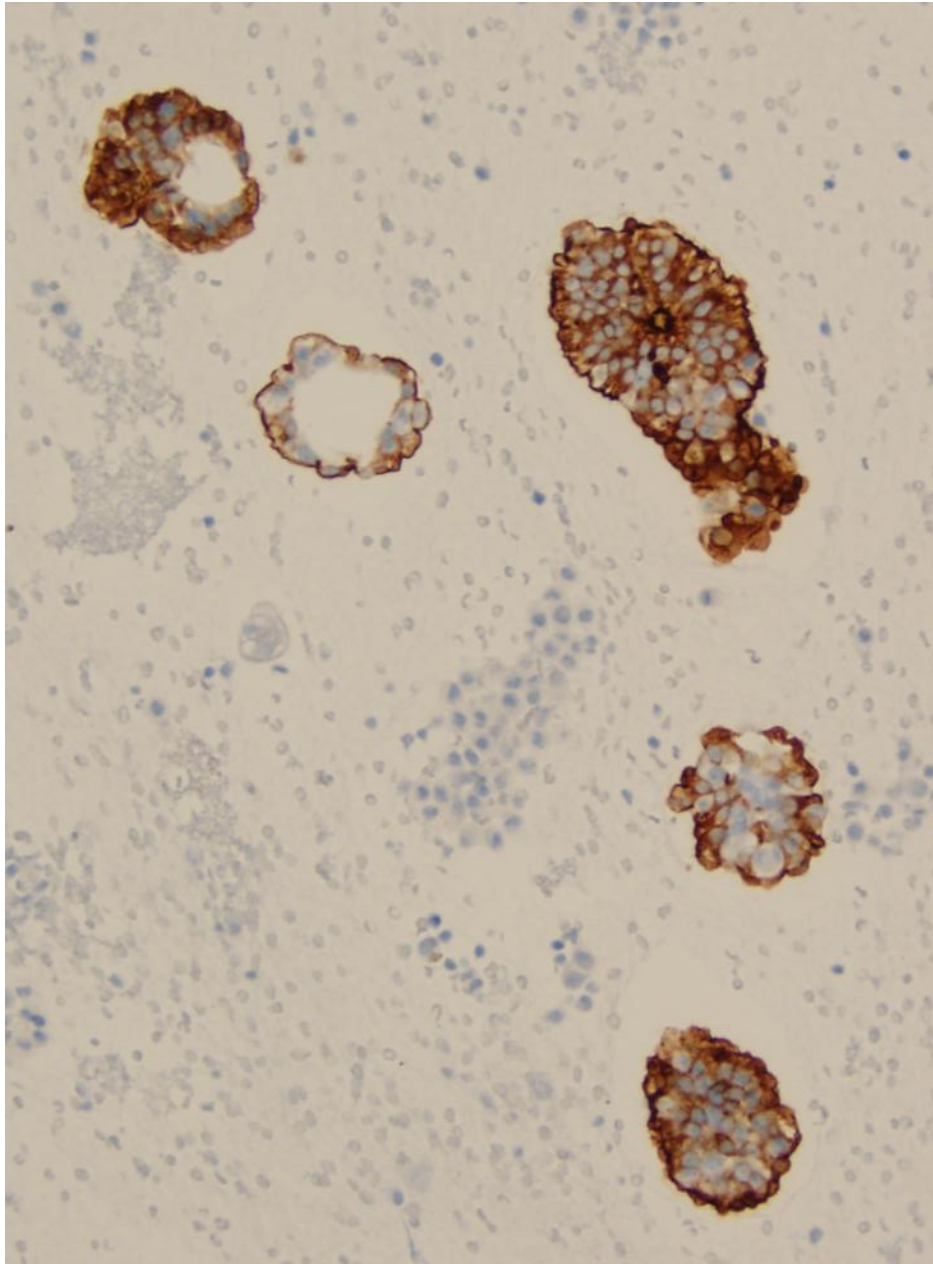
TTF-1



**Our
PSA**



Prostate Specific Membrane Antigen (PSMA)



- Cytoplasmic and membranous
- Prostatic epithelium and urothelium
- Best used to identify metastatic prostatic ADCA
- In contrast to PSA and PSAP expression should be not diminish in higher grade lesions.

The Utility of PSMA and PSA Immunohistochemistry in the Cytologic Diagnosis of Metastatic Prostate Carcinoma

Kurt D. Bemacki, M.D., Kristina L. Fields, B.S.,
and Michael H. Roh, M.D., PH.D.*

The diagnosis of metastatic prostate carcinoma frequently requires the use of immunohistochemical adjuncts. Immunohistochemistry for prostate-specific antigen (PSA) is commonly used for this purpose but can be of limited utility. Recently, prostate-specific membrane antigen (PSMA) has been shown to be a promising marker for the identification of metastatic prostate carcinoma in surgical specimens. The utility of this marker has yet to be reported for cytology specimens. We sought to compare the sensitivities of PSMA and PSA immunohistochemistry and investigate the specificity of PSMA by utilizing cell block preparations from cytologic cases of metastatic prostate carcinoma (n = 19) and carcinomas of nonprostatic origin (n = 33). The sensitivity of PSMA immunohistochemistry was higher (16/19; 84%) in detecting metastatic prostate carcinomas than that of PSA immunohistochemistry (11/19; 58%). Strong, diffuse staining for PSMA was seen in 13 (81%) of 16 PSMA-positive cases whereas strong, diffuse staining for PSA was observed in six (55%) of 11 PSA-positive cases. Positivity for either PSMA or PSA was seen in 17 of 19 cases of metastatic prostate carcinoma for a combined sensitivity of 89%. PSMA immunohistochemistry was completely negative in 32 of 33 cytology cases of nonprostatic carcinomas. Therefore, the specificity of this marker was 97% in this study. In conclusion, our results indicate that PSMA is a highly sensitive and specific immunomarker for the detection of metastatic prostate carcinoma in cytology specimens. Diagn. Cytopathol. 2014;42:570–575. © 2013 Wiley Periodicals, Inc.

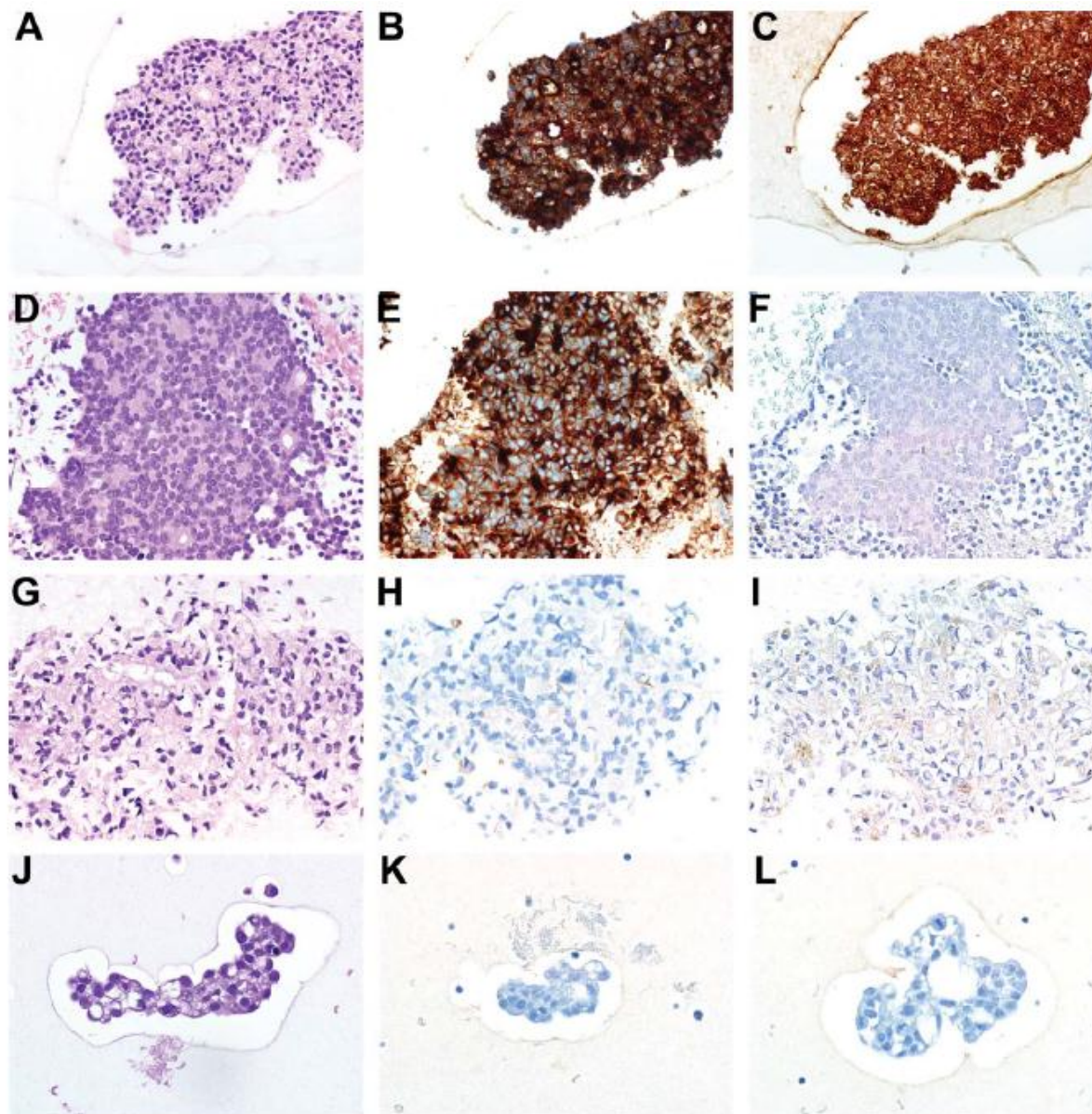


Fig. 1. Immunohistochemistry for PSMA and PSA for cases of metastatic prostate carcinoma. (A, D, G, J) Representative photomicrographs obtained from hematoxylin and eosin (H&E) stained cell block sections derived from cases of metastatic prostate carcinoma (cases 6, 11, 14, and 19, respectively). (B, E, H, K) Corresponding immunohistochemical stains for PSMA expression. In panels B and E, strong diffuse staining for PSMA is demonstrated (combined immunoreactivity score of 6). PSMA immunostains in panels H and K were interpreted as negative. (C, F, I, L) Corresponding immunohistochemical stains for PSA expression. In panel C, strong diffuse staining for PSA is demonstrated (combined immunoreactivity score of 6). The PSA immunostains in panels F and L were interpreted as negative. The PSA immunostain for case 14 (panel I) was interpreted as positive; weak staining intensity was noted in greater than 10% but less than 50% of the tumor cells (combined immunoreactivity score of 3). [Color figure can be viewed in the online issue, which is available at wileyonlinelibrary.com.]

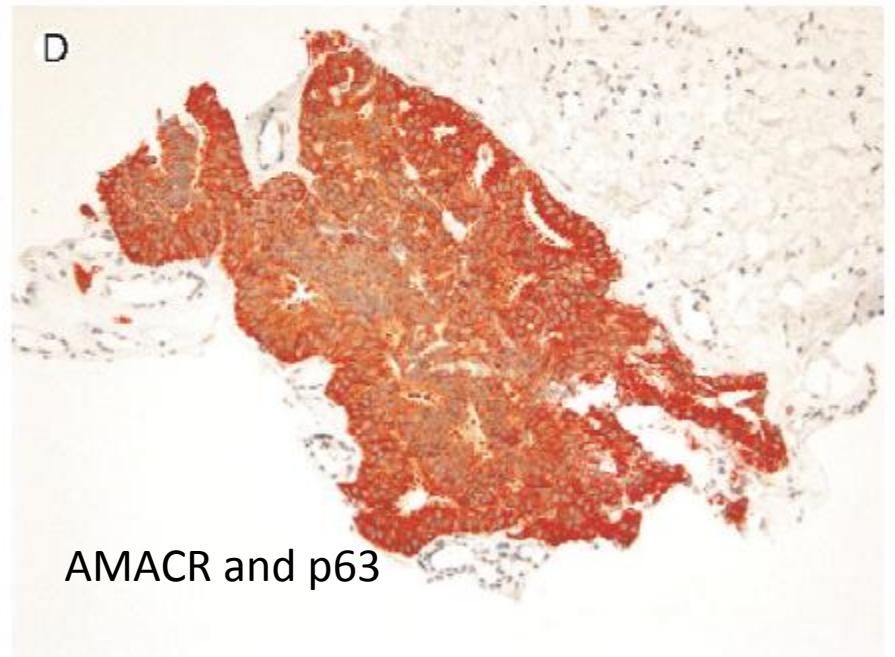
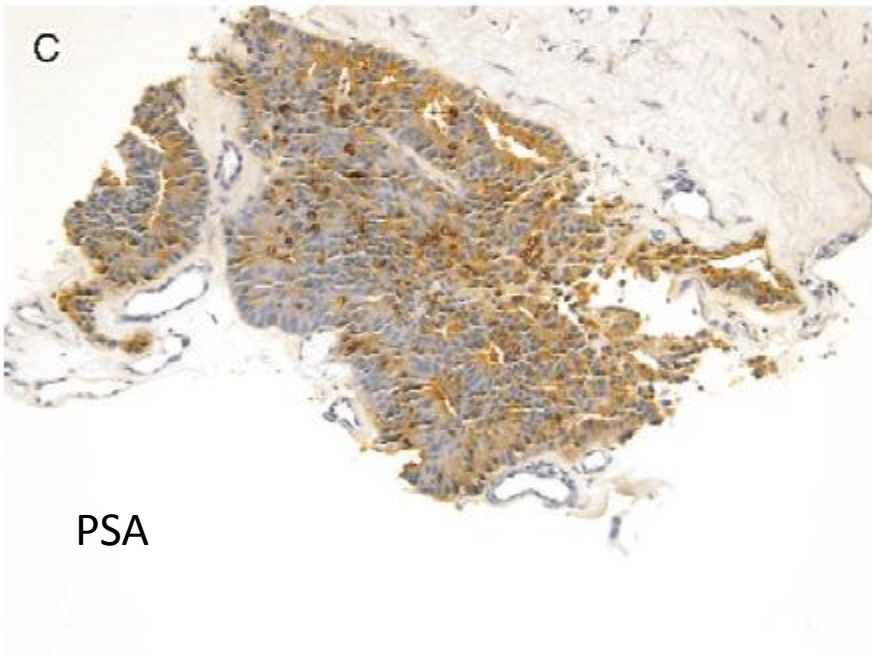
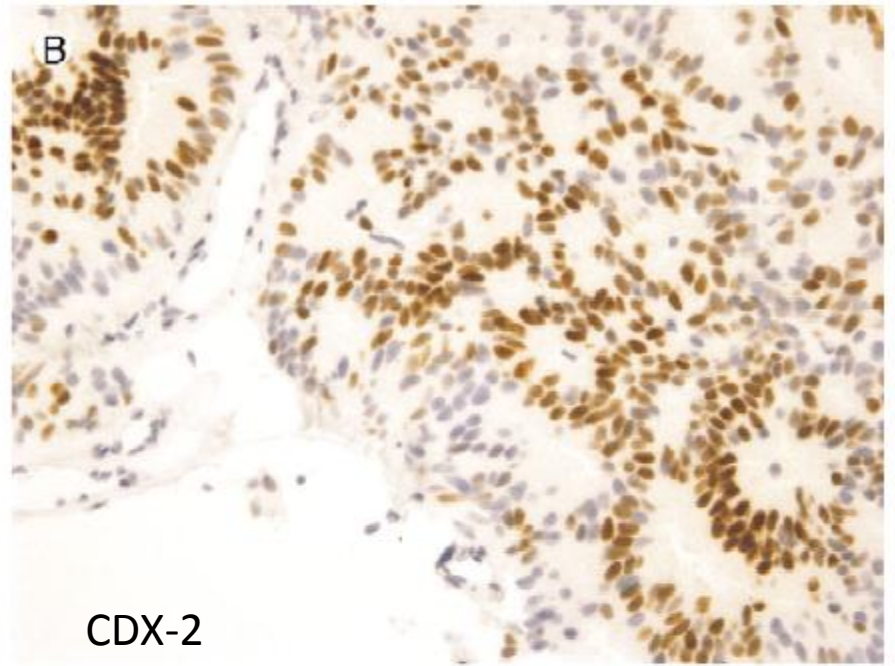
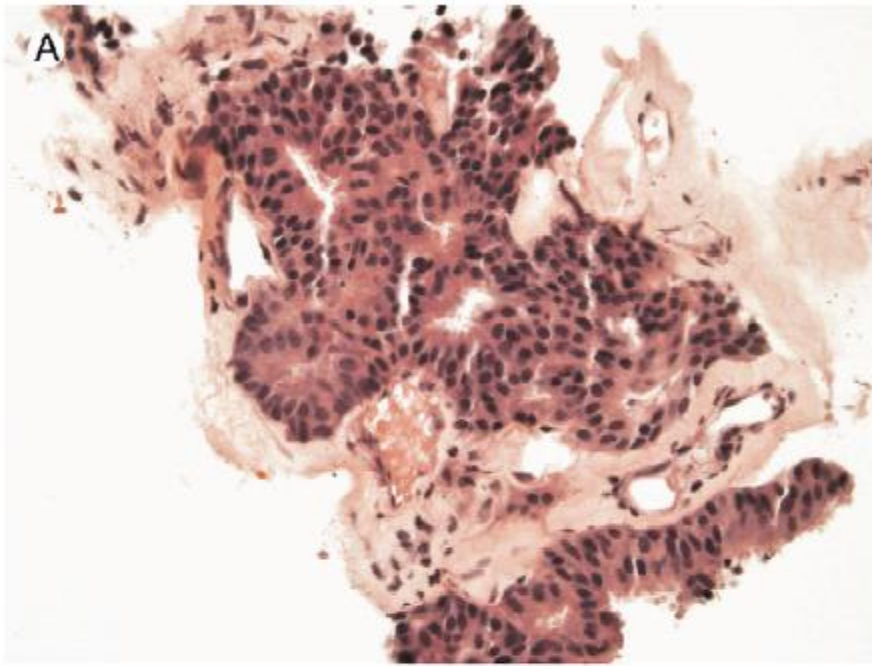
What about CDX-2 ?

Expression of CDX2 in benign tissue and adenocarcinoma of the prostate[☆]

Human Pathology (2007) 38, 72–78

Mehsati Herawi MD, PhD^a, Angelo M. De Marzo MD, PhD^{a,b},
Glen Kristiansen MD^a, Jonathan I. Epstein MD^{a,b,c,*}

- CDX-2 microarray
 - 5.7% of radical prostatectomies were positive
 - Patchy and weaker than colonic tissue
 - Independent of Gleason score
 - Focal moderate staining in benign prostatic stroma (11.7% of cases)
 - No cases of metastatic prostatic adenocarcinoma were positive



Dx

- Positive for metastatic adenocarcinoma, consistent with prostatic origin